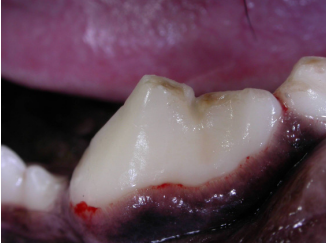

ADDITIONAL PROCEDURES COMMONLY PERFORMED FOR DOGS

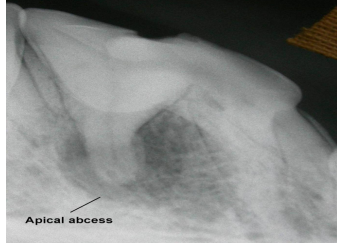
(Conditions that often need to be corrected after 12-step comprehensive cleaning to prevent pain & future problems)

1. CHIPPED TEETH (affects all ages)

Dogs teeth are almost all pointed in shape. They can easily get chips or fractures from chewing on hard objects or trauma with hard objects (anything that hurts you when you hit it against your shin!).



Chipped #108



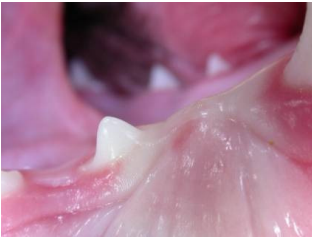Apical Abscess #208

- Painful (MOST pets do not show overt signs of pain).
- Sealants can treat & prevent pain.
- Root canals or extractions may be needed after apical abscess occurs.

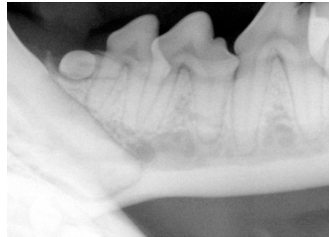
Treatment/Prevention: Sealants are applied to desensitize the tooth and prevent infections. Infections can cause painful apical abscesses, potential loss of tooth and/or expensive oral surgery. EARLY TREATMENT IS BEST!

2. UN-ERUPTED TEETH (impacted or missing usually in young dogs)

Dogs do not always get the right number of teeth! Some teeth do not come in correctly, similar to human wisdom teeth. Common breeds are Shih Tzus, Pugs, Puggles, Cavalier King Charles Spaniels and MANY other small breeds. Out of 42 teeth most dogs have one or more abnormal teeth as detected by dental x-rays.



Un-erupted #405 tooth



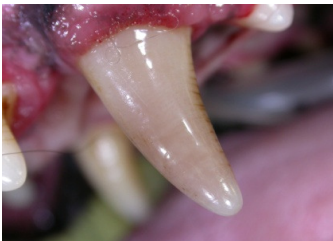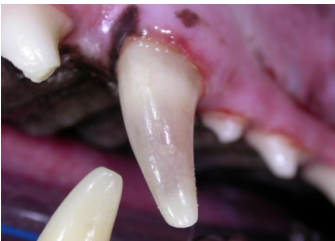Radiograph of un-erupted #305

- Similar to human wisdom teeth
- Painful cysts (dentigerous) can develop.
- If not treated early may destroy bone in jaw bone and nearby teeth.
- Diagnosed by sedated oral exam and

Treatment/Prevention: Dental radiographs and removal of any impacted teeth as soon as detected. If diagnosed before 6 months of age other surgical intervention may be a treatment option (operculectomy).

3. DISCOLORED TEETH (dogs that are aggressive chewers)

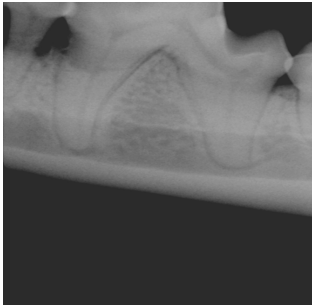
Any off-color tooth: gray, pink, purple or off white is definite evidence of tooth trauma and pain. Most common breeds are Labradors and Golden Retrievers.



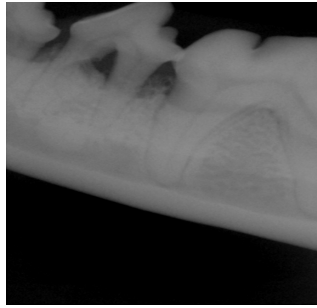
- Are intermittently painful.
- Caused by trauma or hard toys.
- Diagnosed at physical or sedated oral exam

4. PERIODONTAL POCKETS (Found in Grade 3 and Grade 4 Periodontitis usually smaller breeds & older dogs)

In the later stages of periodontal disease (grade 3 and 4) pets commonly have bone loss around the tooth.



Radiograph of Grade 3-4 periodontitis



Radiograph of Grade 4 Periodontitis

- Painful.
- Low grade systemic inflammation and bacteria that affect other organs.
- 100% preventable.